

## Technical Note

# Anatomic Double-Bundle Posterior Cruciate Ligament Reconstruction Using Hamstring Tendons

Andreas C. Stähelin, M.D., Norbert P. Südkamp, M.D., and Andreas Weiler, M.D.

---

**Abstract:** Recent biomechanical studies have shown that an anatomic double-bundle posterior cruciate ligament (PCL) reconstruction is superior in restoring normal knee laxity compared with the conventional single-bundle isometric reconstruction. We describe a modification of an endoscopic PCL reconstruction technique using a double-bundle Y-shaped hamstring tendon graft. A double- or triple-bundle semitendinosus-gracilis tendon graft is used and directly fixed with soft threaded biodegradable interference screws. In the medial femoral condyle, 2 femoral tunnels are created inside-out through a low anterolateral arthroscopic portal. First, in 80° of flexion, the double-stranded gracilis graft is fixed with an interference screw inside the lower femoral socket, representing the insertion site of the posteromedial bundle. In full extension the combined semitendinosus-gracilis graft is pretensioned and fixed inside the posterior aspect of the single tibial tunnel. The double- or triple-stranded semitendinosus tendon is inserted in the higher femoral tunnel, presenting the insertion site of the anterolateral bundle. Finally, pretension is applied to the semitendinosus bundle in 70° of flexion and a third screw is inserted. Using this technique, the stronger semitendinosus part of the double-bundle graft, which mimics the anterolateral bundle of the PCL, is fixed in flexion, whereas the smaller gracilis tendon part (posteromedial bundle) is fixed in full extension. Thus, a fully arthroscopic anatomic PCL reconstruction technique is available that may better restore normal knee kinematics as compared to the single-stranded isometric reconstruction. **Key Words:** Posterior cruciate ligament—Double bundle—Biodegradable interference screw—Hamstring tendon.

---

Until recently, the main interest in knee ligament surgery has been the treatment of the more often injured anterior cruciate ligament (ACL). Lately there seems to be less controversy about its surgical treatment and, hence, in recent years more and more attention has been directed toward clinical and biome-

chanical investigations of the surgical reconstruction of the posterior cruciate ligament (PCL).<sup>1,2</sup> Today, the most common method of surgical replacement of an insufficient PCL involves the patient's own patellar tendon.<sup>3-6</sup> Because there is always some degree of donor-site morbidity associated with harvest of the middle-third patellar tendon,<sup>7,8</sup> there has recently been a trend to prefer the use of hamstring tendons for the replacement of the ACL as well as for the PCL.<sup>9-15</sup>

Traditionally, hamstring tendons grafts are fixed extracortically, away from the original cruciate ligament insertion site,<sup>16-18</sup> thus resulting in a reduced construct stiffness and a possible construct stretch out.<sup>19-22</sup> Recently, a technique for the replacement of the PCL by a single bundle of 4 hamstring tendon strands and direct tendon-to-bone fixation using metallic interference screws was described.<sup>13</sup> Experimental and clinical studies support the fast healing of tendon-to-bone fixation using interference screws.<sup>23,24</sup>

---

*From private practice, Basel Switzerland (A.C.S.); Trauma and Reconstructive Surgery, Sports Traumatology and Arthroscopy Service, Charité, Campus Virchow-Klinikum, Humboldt-University, Berlin (A.W.); and Trauma Department, Albert-Ludwigs University, Freiburg (N.P.S.), Germany.*

*Presented at the 2nd Biennial Congress of the International Society for Sports Traumatology, Knee Surgery, and Arthroscopy, Washington, DC, 1999.*

*Address correspondence and reprint requests to Dr. med. Andreas C. Stähelin, St. AlbanVorstadt 51, CH-4052 Basel, Switzerland. E-mail: kruzlifix@staehelin.ch*

*© 2001 by the Arthroscopy Association of North America  
0749-8063/01/1701-2814\$35.00/0  
doi:10.1053/jars.2001.20661*

In conventional single-bundle PCL reconstruction, it is recommended that femoral graft fixation be placed in the so-called most isometric point.<sup>25-27</sup> However, the normal PCL consists of a posteromedial bundle that is tight in extension, and a stronger anterolateral bundle that is mostly taught in flexion.<sup>28,29</sup> Recent reports have demonstrated the biomechanical superiority of a double-bundle versus a single-bundle PCL reconstruction in restoring normal knee laxity.<sup>30,31</sup> Thus, a double-bundle reconstruction of the PCL mimics more closely the natural behavior of the normal PCL and could therefore restore normal knee laxity across the full range of motion.

To improve the surgical technique of PCL reconstruction, the following endoscopic double-bundle technique and a simple method of posterolateral stabilization with direct tendon-to-bone fixation using biodegradable interference screws has been developed.

## SURGICAL TECHNIQUE

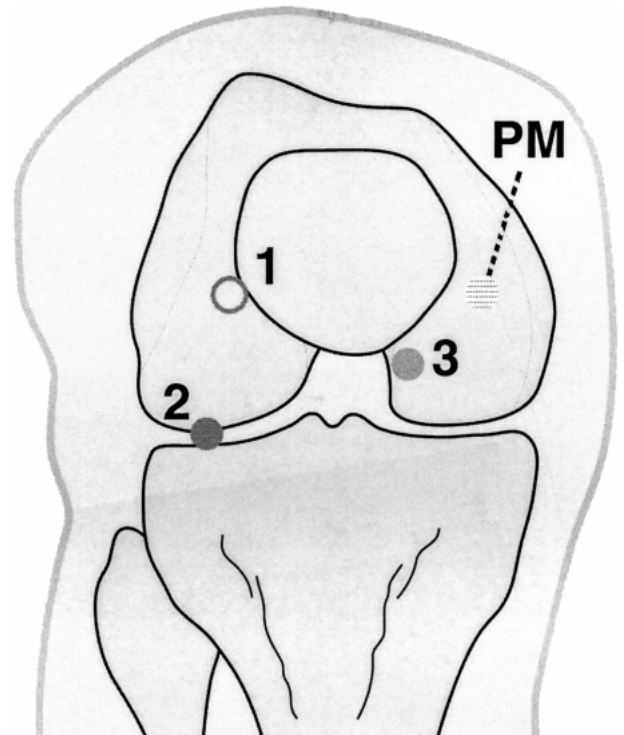
### Arthroscopy Portals

The first arthroscopy portal is a standard high anterolateral portal used for the arthroscope. An additional working portal lies lateral just above the joint line.<sup>32</sup> The third portal lies medial to the patellar tendon just above the tibial plateau (Fig 1). A posteromedial portal is later created under direct arthroscopic vision.

### Graft Harvest and Preparation

The hamstring tendons are harvested through an oblique 3-cm long skin incision along Langer's lines. The semitendinosus tendon is delivered from the posterior aspect of the incision using a tendon hook and is pulled out of the wound after transecting all strands to the gastrocnemius muscle. While the tendons stay attached at their tibial insertion, an open-ended tendon stripper is used for the proximal transection. The second tendon is delivered and transected in the same way.

Each tendon is doubled over a large nonabsorbable holding suture (white suture for the semitendinosus and colored for the gracilis tendon). While tension is applied to both holding sutures, each is secured with a Kocher clamp at its tibial insertion in such a way that the semitendinosus loop is approximately 1 cm longer than the smaller gracilis loop. Alternatively, if long enough, the semitendinosus tendon graft may be tripled for the replacement of the stronger anterolateral

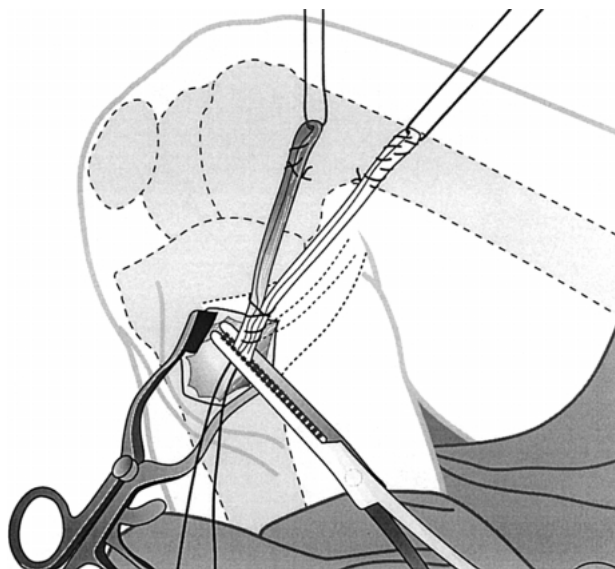


**FIGURE 1.** The arthroscopy portals and skin incisions are marked on the skin with a marking pen (1, high anterolateral arthroscopy portal; 2, low anterolateral working portal; 3, medial working portal; PM, posteromedial portal).

bundle. Using a baseball stitch, the 4 tendon strands are sutured together over a length of 3 cm at the end that is still attached to the tibia. Both loops of the tendon strands are sutured individually over a length of 2 to 2.5 cm using a baseball stitch (Fig 2). The graft is cut off and the length (approximately 9 cm) and the exact diameter of the graft ends are measured using the sizing holes of a graft preparation block. Finally, 4 No. 5 Ethibond sutures (Ethicon, Somerville, NJ) are attached to the distal graft end using a modified Bunnel stitch.

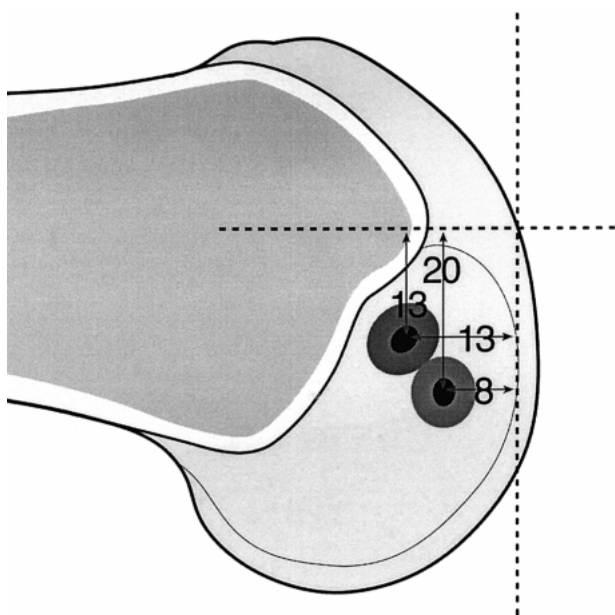
### Tunnel Creation

After a thorough and careful arthroscopic examination of the knee, the knee joint is flexed to 80°. The ruptured PCL is removed from the medial wall of the intercondylar notch. A small remnant is left attached to the medial wall to mark the footprint of the original PCL. The entrance of the more superior of the 2 femoral sockets is marked approximately 13 mm below the top of the roof and 13 mm posterior to the border of the articular cartilage using an angled awl (Fig 3).<sup>33</sup> The more inferior socket entrance is marked



**FIGURE 2.** Both loops of the tendon strands are sutured individually over a length of 2 cm using a baseball stitch.

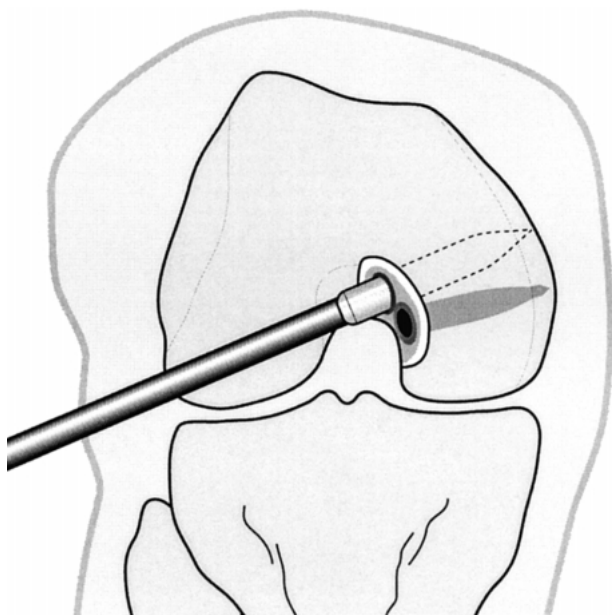
approximately 20 mm down from the top and just 8 mm away from the border of the articular cartilage (Fig 3).<sup>33</sup> A 7-mm blade dilator is inserted through the additional low anterolateral arthroscopic portal into the knee joint. It is driven into the bone at the previ-



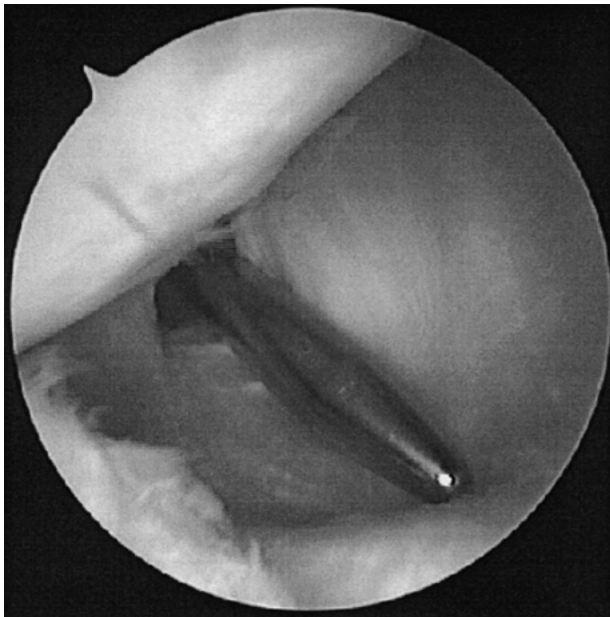**FIGURE 3.** The entrance of the more superior of the 2 femoral sockets is marked approximately 13 mm below the top of the roof and 13 mm posterior to the border of the articular cartilage. The more inferior 20 mm down and 8 mm posterior.<sup>33</sup>

ously marked entry points for the femoral sockets. Once the 40-mm long dilator is inserted about half way, an oscillating motion of the dilator will create a cylindrical hole (Fig 4). In very dense bone, we recommend widening the first few millimeters of the socket entrance to 9 mm.

At this point, one might want to establish an additional posteromedial portal. This portal lies approximately 2 to 3 cm above the joint line. Under direct arthroscopic vision, a long spinal needle is inserted to find the optimal location. Through this portal, under direct vision of the anteriorly introduced arthroscope, the exit of the tibial tunnel can be cleaned of any remnants of the PCL. Thus, the arthroscope may be switched to this posteromedial portal to visualize the future tunnel exit point (Fig 5). The hook of the PCL tibial drill guide is introduced into the knee joint through the anteromedial portal and pushed far back over the top of the tibial plateau (Fig 6). Its correct position is verified under direct arthroscopic vision through the posteromedial portal and, if desired, by fluoroscopy. The entrance to the tunnel has to be located just medial to the tibial tubercle. Under arthroscopic control, a 2.4-mm K-wire is drilled so that its exit point corresponds to the center of the spoon of the tibial drill guide. The length of the tibial tunnel is then measured. The tibial drill guide is removed, leaving

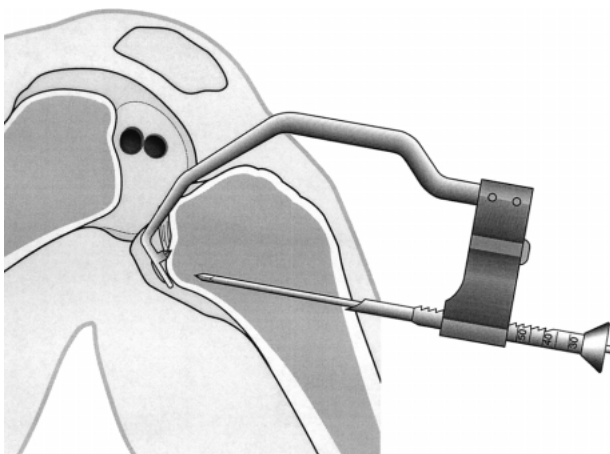


**FIGURE 4.** Once the 40-mm long 7-mm wide femoral dilator is fully inserted, an oscillating motion of the dilator will create a cylindrical hole.



**FIGURE 5.** A Wissinger rod is placed through the posteromedial portal for the insertion of the arthroscope.

the guidewire. The anterior cortex of the tibial tunnel is opened by using a cannulated drill bit, preferably of the same size as the final tibial tunnel diameter over the guidewire. Then the tunnel is dilated using cannulated tibia dilators sizing up to the desired diameter of the tunnel in 1-mm steps up to about 1 cm below the joint. A transtibial tube saw is then used to penetrate the dense subchondral bone and to remove the remnants of the old PCL (Fig 7). Using the hand-driven

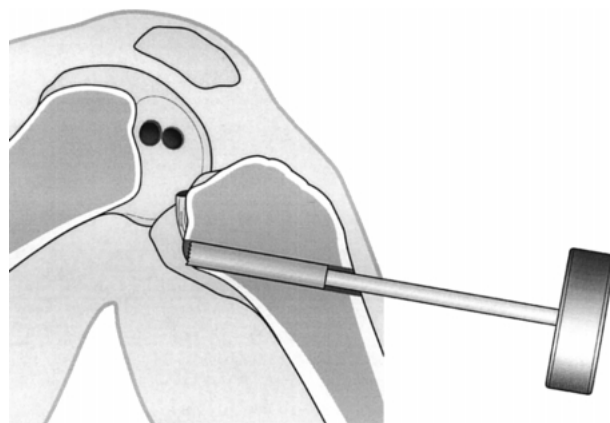


**FIGURE 6.** The hook of the PCL tibial drill guide is introduced into the knee joint and pushed far back over the top of the tibial plateau.

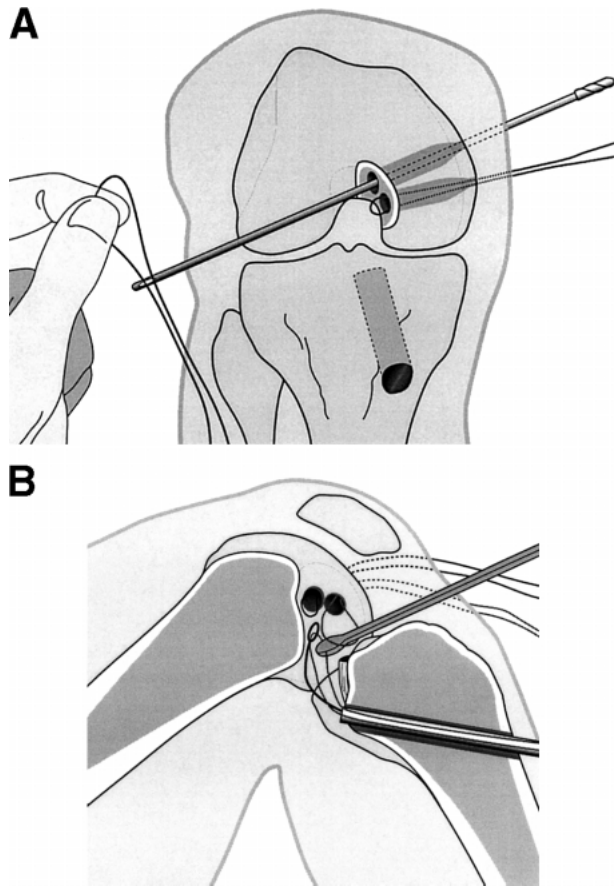
transtibial tube saw, the tunnel exit point can be slightly corrected in any direction. Once the tube saw enters the joint, it is advanced further with an oscillating motion to resect all soft-tissue fibers remaining at the tunnel exit.

### Graft Passage and Fixation

Using a beath pin with suture, a loop of a white nonresorbable suture (for the semitendinosus tendon) is pulled via the anterolateral arthroscopy portal into the superior femoral socket and out of the lateral femoral condyle (Fig 8A). The suture is pulled until a just small loop protrudes out of the femoral socket. Using a pigtail suture passer, a white pull-through suture is inserted into the tibial tunnel and brought over the top of the posterior border of the tibial plateau. An arthroscopic grasper is now inserted through the loop of the previously placed white suture lying inside the superior femoral socket and the suture is pulled out the anteromedial portal (Fig 8B). The suture loop and, with it, the suture coming from the tibial tunnel, is now pulled out of the medial femoral condyle and the skin. The same procedure is performed using a colored pull-through suture for the inferior socket. This way, both pull-through sutures are placed through the tibial tunnel, each into 1 of the femoral sockets. The 2 sutures of the femoral ends of the graft are now tied to the pull-through sutures. The white pull-through suture is attached to the semitendinosus tendon and the colored pull-through suture to the gracilis tendon. The graft is now pulled through the tibial tunnel into the femoral sockets. The graft pas-



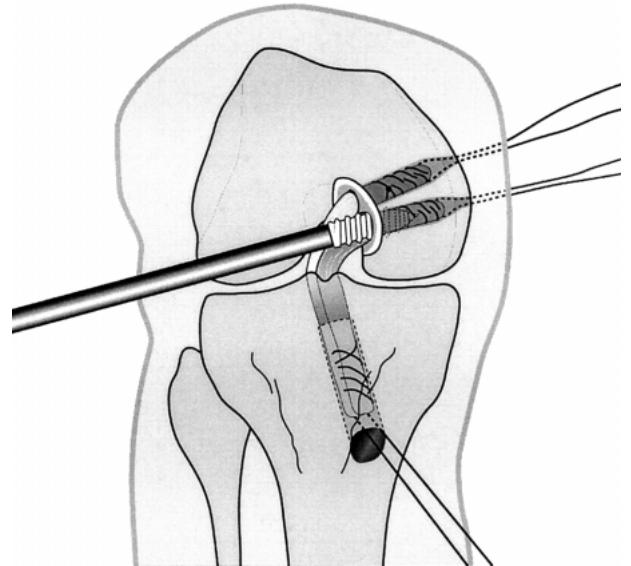
**FIGURE 7.** The tibial tunnel is created by using cannulated dilators in increments of 1 mm. The dorsal tibial cortex is penetrated with a hand held helical tube saw and the remaining soft tissue is removed.



**FIGURE 8.** (A) A beath pin with suture is pulled via the anterolateral arthroscopy portal into the superior femoral socket and out of the lateral femoral condyle. (B) An arthroscopic grasper is inserted through the suture loop and the suture from the tibial tunnel is pulled out the anteromedial arthroscopy portal.

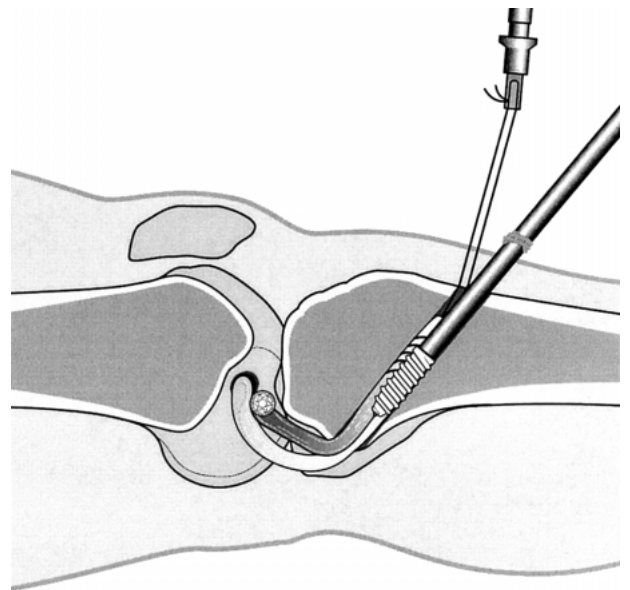
sage can be easily facilitated by inserting a blunt trocar into the posteromedial portal and using it as a fulcrum. Both femoral ends are pulled for at least 25 mm inside the femoral sockets so that the sutures in the tendons are no longer visible.

With the knee flexed to 80°, the gracilis bundle is fixed using the first biodegradable interference screw (Sysorb; Sulzer Orthopedics Ltd, Baar, Switzerland). The screw is inserted from the low anterolateral portal into the inferior femoral tunnel (Fig 9). The graft is held tightly with the holding sutures to prevent the screw from catching some of the superficial graft fibers. The screw is inserted just underneath the joint surface. Then a pretensioning force of 80 N is applied to the tibial end of the graft using the tension isometer. The joint is moved through its full range of motion several times and the knee is brought to the near extension position. Maintaining the pretension to 80



**FIGURE 9.** With the knee flexed to 80°, the first biodegradable interference screw is inserted from the low anterolateral arthroscopy portal into the inferior femoral socket.

N, the tibial biodegradable interference screw is inserted parallel to the graft using a cannulated screwdriver over a small nitinol guidewire (Fig 10). The screw is advanced until the marking on the screwdriver corresponding to the previously measured tunnel length reaches the tibia cortex at the tibial tunnel



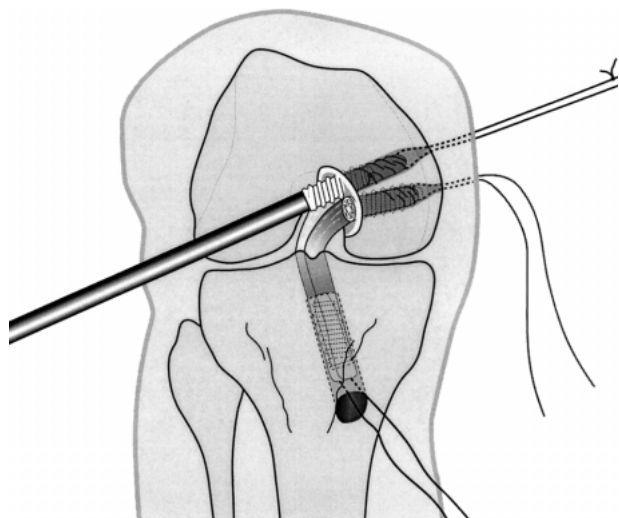
**FIGURE 10.** The tibial biodegradable interference screw is inserted parallel to the graft in full extension using a cannulated screwdriver over a small nitinol guidewire.

entry. The knee is now flexed to  $80^\circ$  and 80-N pretension is applied to the anterolateral semitendinosus loop. Then, the third interference screw is inserted in the same manner (Fig 11). To augment the tibial fixation, we recommend tying the distal holding sutures around a bony bridge at the outer edge of the tibial tunnel. In the final reconstruction, the anterolateral bundle is tight in flexion and the posteromedial is tight in extension (Fig 12).

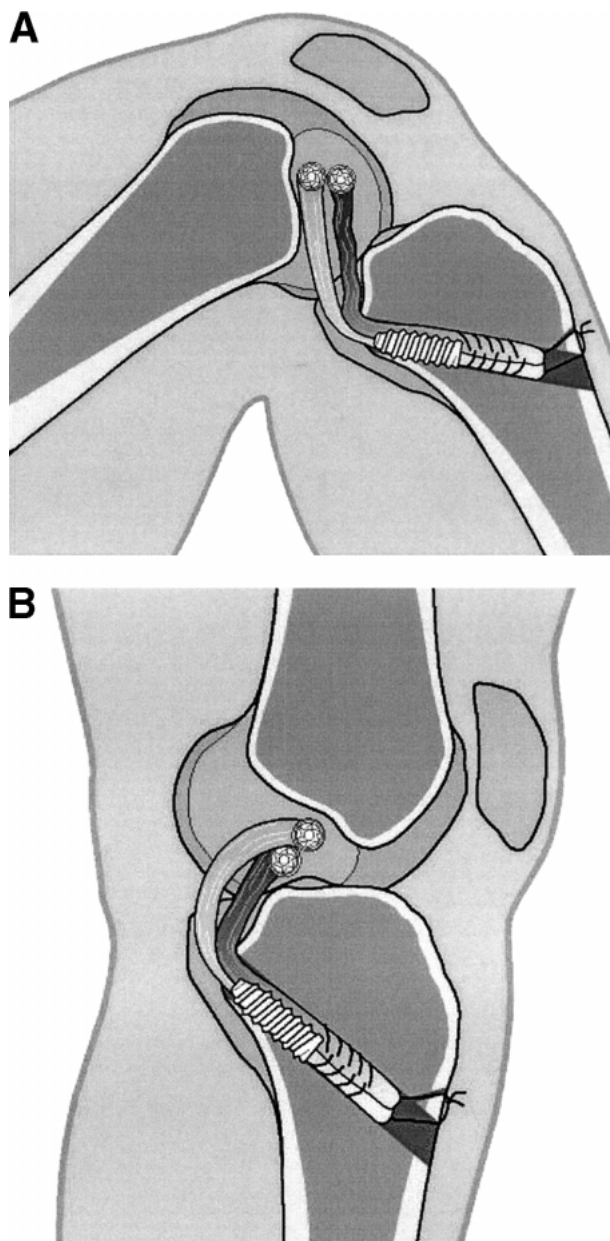
### Posterolateral Stabilization

In cases of more than 12 mm posterior drawer in  $90^\circ$  flexion on stress radiographs, with an increased external rotation or an increased lateral joint opening during arthroscopy, we perform an additional posterolateral stabilization.<sup>34-36</sup> The posterolateral stabilization is modified according to the technique described by Strobel<sup>37</sup> using a semitendinosus tendon harvested from the opposite knee or allograft material.

A 4.5-mm oblique hole is made in the fibular head. The optimal isometric location of the femoral hole should be verified using a suture passed through the tunnel of the fibular head and fixed to the femur using a K-wire (Fig 13). This point lies near the lateral femoral epicondyle at the proximal attachment site of the lateral collateral ligament. Once there is little change in the suture length during a full range of

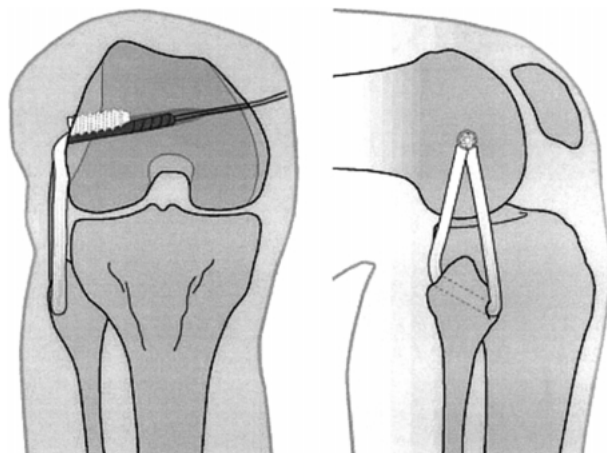
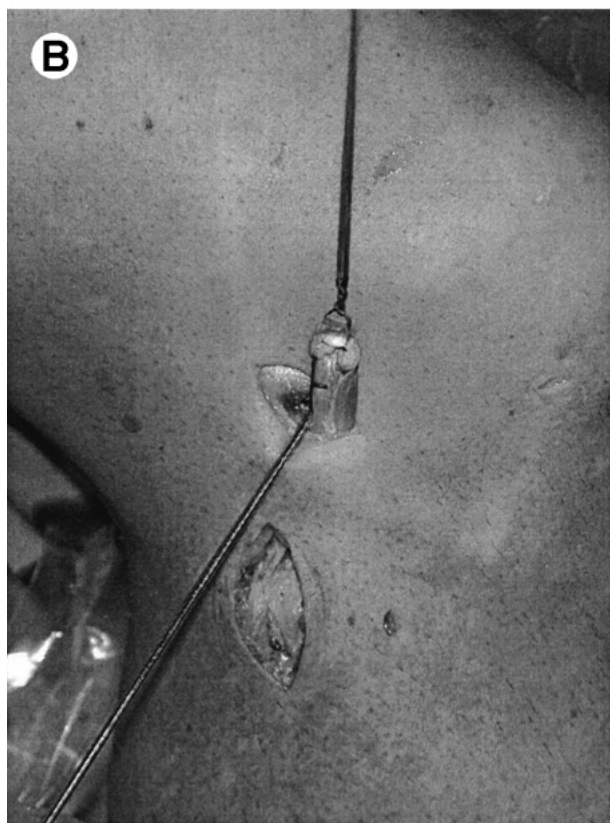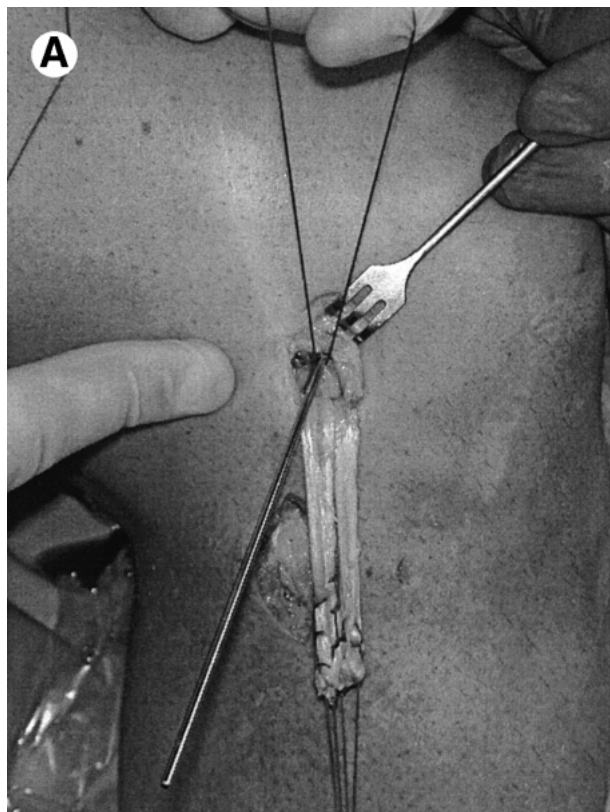


**FIGURE 11.** The third interference screw is inserted in the same way as the first (with the knee flexed to  $80^\circ$ ) in the superior femoral socket.



**FIGURE 12.** In the final reconstruction, (A) the anterolateral bundle is tight in flexion and (B) the posteromedial bundle is tight in extension (b).

motion (approximately less than 2 mm) a 7-mm wide 40-mm long hole is created using the Sysorb screwdriver (Sulzer) first and then the 7-mm dilator. The semitendinosus graft is pulled into the socket using a beath pin. The graft is pretensioned and fixed directly to bone in  $60^\circ$  of flexion and slight internal rotation using a single biodegradable screw (Fig 14).



**FIGURE 14.** Final appearance of the posterolateral reconstruction. The semitendinosus graft is pulled into the socket using a beath pin. The graft is pretensioned and directly fixed to bone using a single biodegradable screw.

### Postoperative Rehabilitation

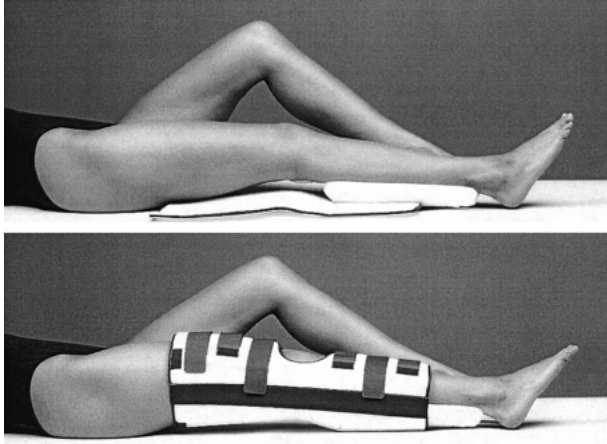
The knee joint is immobilized in full extension using a posterior tibial support brace (PTS Brace; Medi Bayreuth GmbH, Bayreuth, Germany) (Fig 15). This reduces posterior subluxation and is worn for 6 weeks during the day and at night. Quadriceps strengthening exercises are started after the first week and full weight bearing is permitted as tolerated. Passive flexion exercises limited to 90° are performed in the prone position. After 6 weeks, the PTS Brace is worn only at night for another 6 weeks in order to eliminate posterior sagging during the night. During that time, a functional PCL Brace is worn during the day.<sup>2</sup>

### DISCUSSION

The technique of double-bundle PCL reconstruction using hamstring tendons and soft threaded biodegradable interference screws for fixation described in this report offers distinct advantages. The use of autologous hamstring tendons as compared with patellar

←

**FIGURE 13.** To detect the most isometric point, a K-wire is inserted slightly proximal and anterior to the femoral insertion of the lateral collateral ligament. Isometry is checked by an additionally inserted suture during a full range of motion. (A) If suture excursion exceeds approximately 2 mm, the K-wire position has to be changed. (B) The graft is then shortened to the desired length. In this case, an additional EndoPearl device (Linvatec, Largo, FL) is attached to the graft to augment the fixation.



**FIGURE 15.** The PTS Brace locks the knee in full extension. The additional inlay at the calf reduces the posterior subluxation.

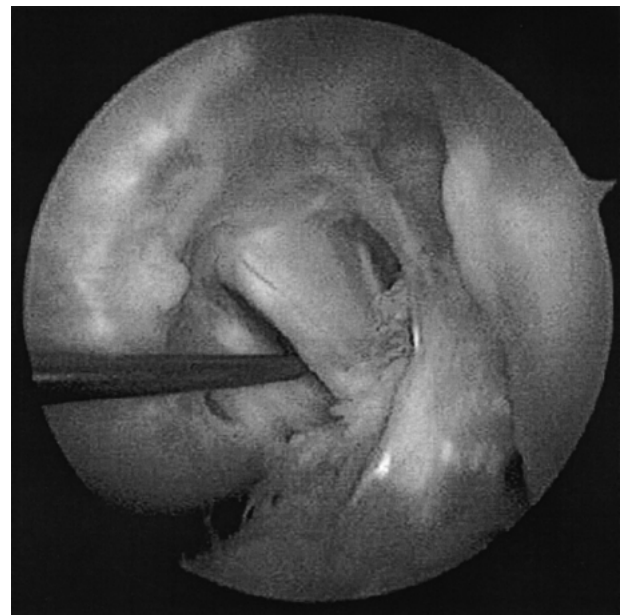
tendon autograft is associated with a reduced harvest site morbidity, and without attached bone plugs, graft-passage is easily facilitated. A single tibial tunnel and 2 femoral sockets allow good restoration of the anatomy of the natural PCL whose fibers diverge widely as they approach the extensive femoral attachment.<sup>38-41</sup> The femoral sockets are created from inside out through an additional low anterolateral working portal as first described by Kim and Min.<sup>32</sup> This makes an incision at the medial femoral condyle unnecessary, thus reducing the overall morbidity.<sup>42</sup> For graft fixation, the interference screws are inserted through the same portal and in the same direction as for the creation of the tunnel. This reduces screw divergence and increases screw fixation strength.<sup>43,44</sup> The use of biodegradable interference screws offers several advantages over their metal analogues, such as undistorted magnetic resonance imaging, uncompromised revision surgery, and a reduced risk of graft laceration during screw insertion.<sup>45-49</sup>

Soft threaded biodegradable interference screws (Sysorb) allow hamstring graft fixation close to the original PCL attachment site, which might increase the immediate postoperative posterior knee stability as was shown for ACL reconstruction<sup>20,50,51</sup> because the free graft length is reduced to its intra-articular portion. Thus, the free part of the graft is no longer than the intra-articular distance, which reduces elastic elongation of the graft construct. Furthermore, anatomic joint line fixation promotes soft-tissue graft incorporation into the bony tunnels.<sup>23,52,53</sup>

In the native PCL, the thinner posteromedial bundle

is tight in extension and the stronger anterolateral bundle is taught in flexion.<sup>28,29</sup> The fixation of the 2 bundles in our method takes this fact into account and the anteromedial bundle is tensioned and fixed in near extension, whereas the anterolateral bundle is anchored in flexion. Race and Amis<sup>31</sup> were able to prove that an anatomic double-bundle PCL reconstruction is superior in restoring normal knee laxity compared with a single-strand, so-called isometric reconstruction.<sup>31</sup>

Fixing the knee joint in full extension first is especially advantageous in cases where both the ACL and PCL are disrupted (Fig 16) and the neutral position of the knee joint cannot be easily detected. Because the medial tibiofemoral joint is congruent, the knee joint can be reduced to neutral with full extension and axial loading, at which time the posteromedial bundle is fixed. If necessary, the additional posterolateral stabilization using the contralateral semitendinosus tendon or allograft material and direct tendon-to-bone interference screw fixation is minimally invasive and effectively reduces increased posterolateral rotatory instability.<sup>37</sup> Our preliminary clinical experiences are encouraging as are those recently reported by Caborn et al.<sup>54</sup> However, long-term data are necessary to finally judge on this new operative procedure.



**FIGURE 16.** Second-look arthroscopy 1 year after combined ACL, PCL, and posterolateral reconstruction. The probe indicates the separation of the anterolateral and posteromedial bundle.



**Acknowledgment:** The authors extend their thanks to Mr. L. Guerriero for the illustrations.

## REFERENCES

1. Harner CD, Höher J. Evaluation and treatment of posterior cruciate ligament injuries. *Am J Sports Med* 1998;26:471-482.
2. Strobel MJ, Weiler A. [Diagnosis and treatment of acute and chronic posterior cruciate ligament insufficiency]. *Chirurg* 2000;71: 1066-1081
3. Lobenhoffer P. [Chronic instability after posterior cruciate ligament injury. Tactics, techniques, and results]. *Unfallchirurg* 1999;102:824-838.
4. Clancy WG, Pandya RD. Posterior cruciate ligament reconstruction with patellar tendon autograft. *Clin Sports Med* 1994; 13:561-570.
5. Jakob RP, Rügsegger M. [Treatment of posterior and posterior-posterolateral knee instability]. *Orthopäde* 1993;22:405-413.
6. Mariani PP, Adriani E, Santori, Maresca G. Arthroscopic posterior cruciate ligament reconstruction with bone-tendon-bone patellar graft. *Knee Surg Sports Traumatol Arthrosc* 1997;5:239-244.
7. Rosenberg JD, Franklin JI, Baldwin GA, Nelson DA. Extensor mechanism morbidity associated with patellar tendon graft harvest for anterior cruciate ligament reconstruction. *Am J Sports Med* 1990;18:560-565.
8. Paulos LE, Wnorowski DC, Greenwald AE. Infrapatellar contracture syndrome: Diagnosis, treatment and longterm follow-up. *Am J Sports Med* 1994;22:440-449.
9. Shino K, Nakagawa S, Nakamura N, Matsumoto N, Toritsuka Y. Arthroscopic posterior cruciate ligament reconstruction using hamstring tendons: One-incision technique with EndoButton. *Arthroscopy* 1996;12:638-642.
10. Howell S, Taylor M. Brace-free rehabilitation with early return to activity for knees reconstructed with double-looped semitendinosus and gracilis graft. *J Bone Joint Surg Am* 1996;78: 814-819.
11. Brown CH, Steiner ME, Carlson EW. The use of hamstring tendons for anterior cruciate ligament reconstruction. Technique and results. *Clin Sports Med* 1993;12:723-756.
12. Rosenberg JD, Deffner KT. ACL reconstruction: Semitendinosus tendon is the graft of choice. *Orthopedics* 1997;20:396-398.
13. Pinczewski LA, Thuresson P, Otto D, Nyquist F. Arthroscopic posterior cruciate ligament reconstruction using four-strand hamstring tendon graft and interference screws. *Arthroscopy* 1997;13:661-665.
14. Strobel MJ. Hinteres Kreuzband. In: Strobel MJ, ed. *Arthroskopische Chirurgie*. Berlin: Springer, 1998;501-565.
15. Hoffmann F, Bäumler U, Reif G, Kinatader T. [Arthroscopic double bundle reconstruction of the posterior cruciate ligament]. *Arthroscopie* 2000;13:41-46.
16. Steiner ME, Hecker AT, Brown CH, Hayes WC. Anterior cruciate ligament graft fixation. Comparison of hamstring and patellar tendon grafts. *Am J Sports Med* 1994;22:240-246.
17. Mecham MD, Paulos LE. Transosseous ligament fixation devices. *Tech Orthop* 1999;14:52-62.
18. Kowalk DL, Steiner ME. Anterior cruciate ligament reconstruction using hamstrings for a two-incision technique. *Tech Orthop* 1998;13:253-261.
19. Höher J, Livesay GA, Ma CB, Withrow JD, Fu FH, Woo SLY. Hamstring graft motion in the femoral tunnel when using titanium button/polyester tape fixation. *Knee Surg Sports Traumatol Arthrosc* 1999;7:215-219.
20. Weiler A, Scheffler S, Göckenjan A, Südkamp NP, Hoffmann RFG. Different hamstring tendon graft fixation techniques under incremental cyclic loading conditions. *Arthroscopy* 1998;14:425-426.
21. Jorgensen U, Thomsen HS. Behavior of the graft within the bone tunnels following anterior cruciate ligament reconstruction, studied by cinematic magnetic resonance imaging. *Knee Surg Sports Traumatol Arthrosc* 2000;8:32-35.
22. Höher J, Scheffler SU, Withrow JD, Livesay GA, Debski RE, Fu FH, Woo SLY. Mechanical behavior of two hamstring graft constructs for reconstruction of the anterior cruciate ligament. *J Orthop Res* 2000;18:456-461.
23. Weiler A, Peine R, Pashmineh-Azar R, Unterhauser F, Hoffmann RFG. Tendon to bone healing under direct interference screw fixation in a sheep model. *Arthroscopy* 1998;14:437-438.
24. Pinczewski LA, Clingeleffer AJ, Otto DD, Bonar SF, Corry IS. Integration of hamstring tendon graft with bone in reconstruction of the anterior cruciate ligament. *Arthroscopy* 1997;13: 641-643.
25. Grood ES, Hefzy MH, Lindenfield TN. Factors affecting the region of most isometric femoral attachments. Part I. The posterior cruciate ligament. *Am J Sports Med* 1989;17:197-207.
26. Markolf KL, Slauterbeck JL, Armstrong KL, Shapiro MS, Finerman GAM. A biomechanical study of replacement of the posterior cruciate ligament with a graft. Part II: Forces in the graft compared with forces in the intact ligament. *J Bone Joint Surg Am* 1997;75:381-386.
27. Petermann J, Gotzen L, Trus P. Posterior cruciate ligament (PCL) reconstruction—An in vitro study of isometry: Part II. Tests using an experimental PCL graft model. *Knee Surg Sports Traumatol Arthrosc* 1994;2:104-106.
28. Race A, Amis AA. The mechanical properties of the two bundles of the human posterior cruciate ligament. *J Biomechanics* 1994;27:13-24.
29. Race A, Amis AA. Loading of the two bundles of the posterior cruciate ligament: An analysis of the bundle function in AP drawer. *J Biomechanics* 1996;29:873-879.
30. Harner CD, Jansushek MA, Kanamori A, Yagi M, Vogrin TM, Woo SLY. Biomechanical analysis of a double-bundle posterior cruciate ligament reconstruction. *Am J Sports Med* 2000; 28:144-151.
31. Race A, Amis AA. PCL reconstruction: In vitro biomechanical evaluation of isometric versus single and double bundle anatomic grafts. *J Bone Joint Surg Br* 1998;80:173-179.
32. Kim SJ, Min BH. Arthroscopic intraarticular interference screw technique of posterior cruciate ligament reconstruction: One-incision technique. *Arthroscopy* 1994;10:319-323.
33. Morgan CD, Kalman VR, Grawl DM. The anatomic origin of the posterior cruciate ligament: Where is it? Reference landmarks for PCL reconstruction. *Arthroscopy* 1997;13:325-331.
34. Harner CD, Vogrin TM, Höher J, Ma CB, Woo SLY. Biomechanical analysis of a posterior cruciate ligament reconstruction. Deficiency of the posterolateral structures as a cause of graft failure. *Am J Sports Med* 2000;28:32-39.
35. Vogrin TM, Höher J, Aroen A, Woo SLY, Harner CD. Effects of sectioning the posterolateral structures on the knee kinematics and in situ forces in the posterior cruciate ligament. *Knee Surg Sports Traumatol Arthrosc* 2000;8:93-98.
36. Strobel MJ, Neumann HS. Instrumentelle Laxizitätsbestimmung. In: Strobel MJ, Neumann HS, eds. *Instrumentelle Stabilitätsbestimmung des Kniegelenkes*. Berlin: Springer, 1996; 30-64.
37. Strobel MJ. Posterolaterale Instabilität. In: Strobel MJ, ed. *Arthroskopische Chirurgie*. Berlin: Springer, 1998;557-561.
38. Harner CD, Livesay GA, Kashiwaguchi S, Fujie H, Choi NY, Woo SLY. Comparative study of the size and shape of human anterior and posterior cruciate ligaments. *J Orthop Res* 1995; 13:429-434.

39. Girgis FG, Marshall JL, Al Monajem ARS. The cruciate ligaments of the knee joint. *Clin Orthop* 1975;106:216-231.
40. Van Dommelen BA, Fowler OJ. Anatomy of the posterior cruciate ligament. A review. *Am J Sports Med* 1989;17:24-29.
41. Wirth CJ, Jäger M. Dynamic double tendon replacement of the posterior cruciate ligament. *Am J Sports Med* 1984;12:39-43.
42. Kim SJ, Shin SJ, Kim HK, Jahng JS, Kim HS. Comparison of 1- and 2-incision posterior cruciate ligament reconstructions. *Arthroscopy* 2000;16:268-278.
43. Pierz K., Baltz M., Fulkerson J. The effect of Kurosaka screw divergence on the holding strength of bone-tendon-bone grafts. *Am J Sports Med* 1995;23:332-335.
44. Lemos MJ, Jackson DW, Lee TQ, Simon TM. Assessment of initial fixation of endoscopic interference femoral screws with divergent and parallel placement. *Arthroscopy* 1995;11:37-41.
45. Weiler A, Windhagen H, Raschke MJ, Laumeyer A, Hoffmann RFG. Biodegradable interference screw fixation exhibits pullout force and stiffness similar to titanium screws. *Am J Sports Med* 1998;26:119-128.
46. Shellock FG, Mink JH, Curtin S, Friedman MJ. MR imaging and metallic implants for anterior cruciate ligament reconstruction: Assessment of ferromagnetism and artifact. *J Magn Reson Imaging* 1992;2:225-228.
47. McGuire DA, Barber FA, Elrod BF, Paulos LE. Bioabsorbable interference screws for graft fixation in anterior cruciate ligament reconstruction. *Arthroscopy* 1999;15:463-473.
48. Barber FA, Elrod BF, McGuire DA, Paulos LE. Preliminary results of an absorbable interference screw. *Arthroscopy* 1995; 11:573-588.
49. Weiler A, Hoffmann RFG, Stähelin AC, Helling HJ, Südkamp NP. Current concepts: Biodegradable implants in sports medicine—The biological base. *Arthroscopy* 2000;16:305-321.
50. Ishibashi Y, Rudy TW, Livesay GA, Stone JD, Fu FH, Woo SLY. The effect of anterior cruciate ligament graft fixation site at the tibia on knee stability: Evaluation using a robotic testing system. *Arthroscopy* 1997;13:177-182.
51. Johnson DH, Houle JB, Almazan A. Comparison of intraoperative AP translation of two different modes of fixation of the grafts used in ACL reconstruction. *Arthroscopy* 1998;14:425 (abstr).
52. Weiler A, Scheffler SU, Südkamp NP. Current concepts for hamstring tendon graft fixation in cruciate ligament surgery. *Chirurg* 2000;71:1034-1044.
53. Brand J, Weiler A, Caborn DNM, Johnson DL, Brown CH. Graft fixation in cruciate ligament surgery: Current concepts. *Am J Sports Med* 1999;28:761-774.
54. Caborn DNM, Hester P, Sumida K, Selby. A surgical technique: PCL reconstruction using semitendinosus and gracilis as a double bundle/Y structure through standard anteromedial and anterolateral portals with bioabsorbable interference screw fit fixation. *Arthroscopy* 2000;16:419 (abstr).